

See discussions, stats, and author profiles for this publication at: <https://www.researchgate.net/publication/369189648>

# A Case Study of Systemic Lupus Erythematosus in a Female Patient

Article · March 2023

DOI: 10.52314/gjms.2022.v2i3.83

---

CITATION

1

---

READS

61

2 authors:



Suvam Banerjee

Burdwan Medical College

20 PUBLICATIONS 33 CITATIONS

SEE PROFILE



Elina Semenenko

Paula Stradiņa Klīniskā Universitātes Slimnīca

4 PUBLICATIONS 7 CITATIONS

SEE PROFILE

# A Case Study of Systemic Lupus Erythematosus in a Female Patient

Suvam Banerjee<sup>1</sup>, Elina Semenenko<sup>2</sup>

1. Department of Health and Family Welfare, Government of West Bengal, Burdwan Medical College and Hospital (WBUHS) India;  
2. Department of Neuro-psychology, Maastricht University, Netherlands\*

## ABSTRACT

Systemic Lupus Erythematosus (SLE) is the most common form of autoimmune disease which affects different systems of our body such as cardiovascular, nervous, respiratory, gastrointestinal, genitourinary, musculoskeletal, integumentary and immune systems. The most common patients' complaints include problems with the skin, joints and kidneys. Symptoms vary from mild to severe, and if untreated, may result in lethal consequences. Currently, the onset of the disease is not known, and the cure for SLE is still to be found, but there exist various treatment options, which can support the patient in returning to normal life.

The importance of this case report lies in the fact that it is a very rare case, and hence can be of great clinical significance and source of learning for clinicians. This is quite a unique case which highlights the association of disease with its symptoms by comparing its possible differential diagnoses, management from the history of patients to diagnosis and the unique approach undertaken in treatment.

A 22-year-old female was hospitalized with the symptoms of angina, alopecia, oral ulcers and arthralgia. After extensive blood urinary analyses and renal biopsy, the patient was diagnosed with SLE. As for the final treatment decision, the patient was prescribed corticosteroids primarily for 6 months. During treatment, the condition of the patient has improved and during post-treatment, no follow-up complaints have been registered.

In summary, this case study might enhance the facility to report novel findings and better-quality therapeutic strategies. With quick, brief writing and publication rates, case studies are an essential tool for rapidly expanding the growing body of clinical knowledge.

**Keywords:** Lupus, Systemic Lupus Erythematosus, Autoimmune Disease, Corticosteroids

\*See End Note for complete author details

## INTRODUCTION

Systemic Lupus Erythematosus (SLE) is the most common form of autoimmune disease where the body's immune system mistakenly attacks healthy tissues, perceiving them as pathogens.<sup>1</sup> The disease affects different systems of our body such as the cardiovascular, nervous, skeletal, lymphatic and urinary systems. Common symptoms of this disease include pyrexia, angina pectoris, alopecia, polyarthritis, stomatitis, overall fatigue and emaciation, lymphadenopathy and dermatitis as a red rash on the face in form of a butterfly.<sup>2</sup> This disease is considered to be of sporadic origin, with some chance to be transferred genetically, as one study shows.<sup>3</sup> Women of childbirth age fall at the 9 times higher risk of

SLE development compared to men, and specifically, those of Caribbean, African and Asian descent are considered to more likely to develop SLE, with the typical onset of SLE is considered to be from 15 to 45 years.<sup>4</sup> Though there is no cure for SLE at the moment, various treatment options are available, one of the most popular treatments being the prescription of corticosteroids or nonsteroidal anti-inflammatory drugs (NSAIDs), as well as cytotoxic drugs.<sup>5</sup> With the treatment, the prognosis for patients is optimistic, with 80-90% of patients having a normal life span and optimal quality of life.<sup>6</sup> The absence of treatment can lead to severe consequences and even result in the death of a patient, which is why it is highly recommended to timely start treatment immediately after its diagnosis.

*Cite this article as:* Banerjee S, Semenenko E. A Case Study of Systemic Lupus Erythematosus in a Female Patient. Global Journal of Medical Students. 2022;2(3):14-8.

Submitted 29-08-2022

Accepted 21-02-2023

Published 11-03-2023



Access this Article Online

Scan this QR Code

<https://doi.org/10.52314/gjms.2022.v2i3.83>

Corresponding author:

Dr. Suvam Banerjee  
2/3, Dewangazi Road, Bally, Howrah-711201, West Bengal, India.  
Phone: +918777659706  
E-mail: banerjeesuvam1@gmail.com

Table 1. The list of performed investigations from patient's blood sample

Investigations performed	Result, SI units	Normal range, SI units
24-hour urinary protein, antinuclear counter acting agent titer 1:2560 with homogeneity on immunofluorescence	5 g/dL	< 10 mg/dL
Anti ds-DNA titer	>1800 IU/mL	< 30.0 IU/mL
Anti- Smith antibody	164 U/mL	0-7 U/mL
Anti- ribonucleoprotein antibody	132 U	< 20 U
Anti-Sjorgen-syndrome related antigen A	142 U/mL	< 7 U/mL
Anti-Sjorgen-syndrome related antigen B	45 U/mL	< 7 U/mL
Antineutrophil cytoplasmic antibody	Extremely low	Negative: $\leq 19$ AU/mL.
Equivocal: 20-25 AU/mL.	963	940
Positive: $\geq 26$ AU/mL	886	914
Complement C3	40 mg/dL	88-201 mg/dL
Complement C4	5 mg/dL	16-47 mg/dL
Anticardiolipin immunoglobulin M (IgM)	positive	negative
Anticardiolipin immunoglobulin G (IgG)	positive	negative
Lupus anticoagulants	negative	negative
$\beta 2$ -glycoprotein	negative	negative

### Patient information

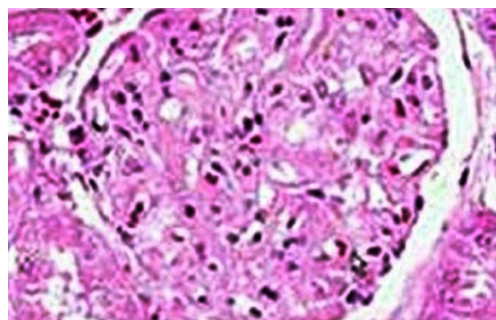
A 22 years old female, resident of West Bengal, India was introduced to the medical clinic with manifestations of shortness of breath, angina, and bilateral pedal oedema since last month. Additional complaints included alopecia, oral ulcers, and arthralgia in both knees. No information about the duration of symptoms was received, though the patient admitted that symptoms have occurred sporadically. There was no significant history of past interventions. There was no relevant medical, family or psycho-social history including genetic information for this patient. The patient was conscious during the admission day and experienced no altered cognitive and mental state or any complication. During clinical examination, the blood pressure was raised (160/90 mmHg) along with the malar rash and generalized oedema. The patient's hemogram reported haemoglobin of 8.8 g/dL, platelet count 118,000/ $\mu$ L, and serum creatinine 2.90 mg/dL with 3+ protein and 3+ haemoglobin on urinalysis.

### Clinical Findings & Diagnostic Assessment

After medical interviewing, several additional clinical investigations such as diagnostic tests have been performed to rule out SLE. All laboratory investigations are provided as follows in **Table 1**.

A renal biopsy was performed which showed proliferative glomerulonephritis with crescents including 7 out of 24 glomeruli on light microscopy (depicted in **Figure 1**). Likewise, there were fibrin thrombi with degenerated RBCs inside some glomeruli. It also reported mesangiolytic, endothelial proliferation, and wrinkling of the glomerular basement membrane. Ultrastructural studies reported early membranous nephropathy. In the immunofluorescence study, there was granular staining of mesangial components for IgG (4+), IgA (2+), IgM (2+), C3 (4+), and C1q (4+). Thrombi stained is positive for fibrinogen. Overall, it revealed lupus nephritis Class III and IV with thrombotic microangiopathy (TMA). The diagnostic challenges included limited resources, difficulties in getting access to testing and financial or religious issues.

As can be seen from analyses, the diagnostic tests which are mentioned are the modes of exclusion for all the differential diagnoses. Differential diagnosis of SLE was put following Differential Diagnosis of Systemic Lupus Erythematosus criteria.<sup>7</sup> The following differential diagnoses have been considered within this patient: adult-onset still disease (distinguishing features of this are: arthralgia, pyrexia, lymphadenopathy, splenomegaly); Behcet syndrome (aphthous ulcers, arthralgia, uveitis); chronic fatigue syndrome (persistent and unexplained fatigue that significantly impairs daily activities); endocarditis (arterial emboli, arthralgia, pyrexia, heart murmur, myalgia); fibromyalgia (poorly localized pain above and below waists on both sides, involving neck, back and chest); psoriatic arthritis (psoriasis before joint disease, nail changes in fingers and toes); rheumatoid arthritis (morning joint stiffness lasting more than one hour; affected joints are usually symmetric, tender, and swollen). Different diagnostic approaches were undertaken to rule out these differential diagnoses which include complete blood count, ESR, CRP, thyroid profile including TSH, tests for leucocytosis and anaemia, blood culture, echocardiography, Western Blot assay for detection of HIV antibodies, serology assessments,



**Figure 1. The renal biopsy of the patient showing proliferative glomerulonephritis with crescents in a case of systematic Lupus Erythematosus**

tests for hypergammaglobulinemia, positive anti-U1RNP antibodies, tests for RA factor or Anti-CCP antibodies, synovial fluid examination, chest radiography and tests for specific autoantibodies. Based on the negative findings of these multiple diagnostic tests so performed to rule out the differential diagnoses, then it was concluded that the final diagnosis of the patient was SLE. The diagnosis of Systemic Lupus Erythematosus was confirmed by following The American College of Rheumatology criteria.<sup>10</sup> Despite a better understanding of the disease process and its advancement in treatment strategies, SLE is still considered to have a poor prognosis.

The management of SLE focuses primarily on the medical or pharmacological management of the systemic manifestations. Hence, it's critical to discuss the choice of management of the disease in detail. The patient got 3 days of glucocorticoid steroids (1 g intravenous methylprednisolone), followed by oral prednisone 100 mg daily. She was furthermore given intravenous cyclophosphamide. The rationale behind this initial therapy choice is that for many decades, corticosteroids and cyclophosphamide have been considered the primary mode of treatment for SLE. Due to their anti-inflammatory properties in the short term and immunosuppressive actions in the long term as defined by their mechanism of action, they are considered to be highly efficacious in the management of the disease. However, in our case report, following ten days of treatment unfortunately her renal profile didn't show any signs of improvement. Important follow-up diagnostic tests were performed which include a complete blood count, peripheral blood smear examination and metabolic parameters panel. Though the patient and her family members reported intervention adherence and its good tolerability, there was no other scientific evidence available to assess the same. Her haemoglobin and platelet levels also continued to decline, at 6.1 g/dL and 45 k/mcL, independently. The peripheral blood smear showed 2 to 3 schistocytes per 50x high-power field. Further lab evaluation showed haptoglobin <30 mg/dL, lactate dehydrogenase 339 U/L, and a positive direct Coombs test. ADAMTS13 activity was 75% (normal: >61%).

We then added tocilizumab, a humanized monoclonal antibody (mAb) against the alpha-chain of IL-6 receptor which prevents the binding of IL-6 to membrane-bound and soluble IL-6 receptor, to the treatment plan for this patient. The purpose of adding this drug was to improve her renal parameters as well as her haematological parameters which were not showing any signs of improvement with our initial therapy choice. Following a half year of tocilizumab, cyclophosphamide, and glucocorticoid steroids, the patient's haemoglobin and platelet levels improved to 12.4 g/dL and 165 k/mcL, independently. Her creatinine level gradually decreased to 0.7 mg/dL.

As for the final treatment decision, the patient was prescribed corticosteroids primarily for 6 months. During treatment, the condition of the patient has improved and during post-treatment, no follow-up complaints have been registered.

## DISCUSSION

This study was introduced to understand the association between SLE with Lupus Nephritis and thrombotic microangiopathy. The clinical classification of Lupus Nephritis is framed by the World Health Organization (WHO). The patient presented with lupus erythematosus (SLE), quickly advancing glomerulonephritis brought about by lupus nephritis, and TMA. TMA can be brought about by hemolytic uremic syndrome (HUS), thrombotic thrombocytopenic purpura (TTP), harmful hypertension, or medications.<sup>8</sup> HUS is characterized by the presence of renal compromise, thrombocytopenia, and microangiopathic hemolytic anaemia. Traditionally, HUS is related to diarrhoea caused by the Shiga toxin of *Escherichia coli* disease. However, 5% to 10% of HUS cases are delegated atypical HUS (aHUS) because the condition isn't preceded by diarrheal ailment.<sup>9</sup> This is interestingly a rare condition that is caused by unrestrained activation of the alternative complement pathway. For patients with immune system illnesses, SLE might give simultaneous HUS and TMA, for example, for this situation.

There are several other clinical case studies in patients which report different types of autoimmune diseases of diverse origins and pathogenesis. There can be different types of Lupus diseases other than SLE which include Discoid lupus erythematosus, Subacute cutaneous lupus erythematosus, drug-induced lupus and lupus in the neonates. SLE has a relapsing/ remitting multisystemic involvement which characteristically helps to differentiate it from other types of Lupus diseases. Also, it is clinically important to compare and differentiate between the types of origin of the disease- familial or sporadic. Studies report that familial cases of SLE are more likely to present at a younger age of 20 years while sporadic cases at 26 years. However, they are broadly similar and it is justified to include multiple case families in genetic studies. Since there can be a variety of autoimmune disorders which are similar to SLE, discussion regarding the comparison of SLE with other cases become important. These 'Lupus mimics' include Rheumatoid arthritis, rosacea and dermatitis, dermatomyositis, undifferentiated connective tissue disorders, Hashimoto's disease, Sjogren's syndrome and fibromyalgia. Clinically, SLE must be differentiated from other similar cases by its distinguishing clinical features in patients- pyrexia, anorexia, weight loss, extreme fatigue and malaise, ipsilateral arthralgia,

dermatitis, myalgia and weakness. Different diagnostic approaches must be undertaken to compare which include complete blood count, ESR, CRP, thyroid profile including TSH, tests for leucocytosis and anaemia, blood culture, echocardiography, Western Blot assay for detection of HIV antibodies, serology assessments, tests for RA factor or Anti-CCP antibodies, synovial fluid examination, chest radiography and tests for specific autoantibodies and other relevant autoimmune parameters etc. Based on the findings of these multiple diagnostic tests, we can compare and distinguish SLE from different types of other autoimmune disorders. Management of autoimmune diseases includes steroids, DMARDs (Disease Modifying Anti-rheumatic Drugs) and other immunosuppressants including monoclonal antibodies etc, each specific for a particular type of disease. Hence, it is important to compare all the clinical findings of SLE with that of other cases starting from history to patient management.

It is also often difficult to distinguish aHUS from TTP as both conditions are present with hemolytic anaemia, thrombocytopenia and end-organ damage. To do so, it is necessary to check ADAMTS13 activity, which is typically normal in aHUS and very low (<5%) in TTP. Autoimmune inhibitors against ADAMTS13 can be found in most cases of TTP, unless a small subset of patients has a genetic mutation in ADAMTS13 activity, thus making it difficult to correctly diagnose and distinguish aforementioned conditions. In contrast to TTP, aHUS is not mediated by ADAMTS13 deficiency. Additionally, antibodies against regulatory proteins have been also implicated in the development of aHUS. As a result, the alternative complement pathway undergoes extensive formation of the membrane attack complex consisting of complement factor C5b-9, which leads to vascular endothelial damage and thrombosis.

The rationale for this case study lies in the fact that it is a unique case report which might enhance the facility to report novel findings and better-quality therapeutic strategies. With quick, brief writing and publication rates, case studies are an essential tool for rapidly expanding the growing body of clinical knowledge. The significance of this case report lies in the fact that it is a very rare case, and hence can be of great clinical significance and a source of learning for clinicians. This is quite interesting as it highlights the association of disease with its symptoms by comparing its possible differential diagnoses, management from the history of patients to diagnosis and the unique approach undertaken in

treatment. As the main limitation of this case study report, diagnostic challenges can be outlined. Practical feasibilities and laboratory resources were limited, therefore not all the required diagnostic tests for differential diagnoses of SLE could be conducted.

## PATIENT'S PERSPECTIVE

“So, when I became sick, I had neglected my health problems initially. My family has a lot of financial constraints so I didn't initially disclose my health problems to my husband. As days passed and I gradually became more ill, my husband noticed the sudden deterioration in my health and brought me to this government hospital. The healthcare providers have been extremely caring and ordered the tests to be performed at their earliest convenience. Following the diagnosis of my disease from the performed diagnostic tests and treatment, my health problems didn't improve initially. After ten days of treatment, I came back for a follow-up and reported the health problems I was facing then. Hearing my complaints, my treatment plan was changed accordingly and I started to improve gradually. Now I am much better and I thank God for this. Also, I like to give special thanks to all my dear doctors, nurses and other healthcare providers for all your support and cooperation during my days of illness.”

## END NOTE

### Author Information

1. Suvam Banerjee, MBBS, Clinical intern  
Department of Health and Family Welfare, Government of West Bengal, Burdwan Medical College and Hospital (WBUHS)India.
2. Dr. Elina Semenenko MS (Neuro-psychology)  
Clinical Neuro-psychologist, Department of Psychology and Neuroscience, Maastricht University, Netherlands

**Conflict of Interest:** None declared

**Participant consent:** Written informed consent for publication of the clinical details was obtained from the patient. As informed consent was taken from the patient, the patient was taken into confidence that the data will only be used solely for research purpose, and her confidentiality was maintained.

## REFERENCES

1. Handout on Health: Systemic Lupus Erythematosus [Internet]. February 2015. Archived from the original on 17 June 2016. Retrieved 12 June 2016.
2. Danchenko N, Satia JA, Anthony MS. Epidemiology of systemic lupus erythematosus: a comparison of worldwide disease burden [Internet]. *Lupus*. 2006;15(5):308-318.
3. The Cleveland Clinic Intensive Review of Internal Medicine. 5th ed. Lippincott Williams & Wilkins; 2012, p. 969. ISBN 9781451153309. Retrieved 13 June 2016.
4. Lisnevskaja L, Murphy G, Isenberg D. Systemic lupus erythematosus [Internet]. *Lancet*. November 2014;384(9957):1878–1888.
5. Fernandes Moça Trevisani V, Castro AA, Ferreira Neves Neto J, Atallah AN. Cyclophosphamide versus methylprednisolone for treating neuropsychiatric involvement in systemic lupus erythematosus. *Cochrane Database Syst Rev*. 2013 Feb 28;2013(2):CD002265.
6. Murphy G, Isenberg D. Effect of gender on clinical presentation in systemic lupus erythematosus. *Rheumatology (Oxford)*. 2013 Dec;52(12):2108–15.
7. Lam NCV, Ghetu MV, Bieniek ML. Systemic Lupus Erythematosus: Primary Care Approach to Diagnosis and Management. *Am Fam Physician*. 2016 Aug 15;94(4):284–94.
8. Trachtman H. HUS and TTP in Children [Internet]. *Pediatr Clin North Am*. 2013 Dec;60(6):1513-26.
9. Fremeaux-Bacchi V, Fakhouri F, Garnier A, Bienaimé F, Dragon-Durey MA, Ngo S, et al. Genetics and outcome of atypical hemolytic uremic syndrome: a nationwide French series comparing children and adults. *Clin J Am Soc Nephrol*. 2013 Apr;8(4):554–62.
10. Hochberg MC. Updating the American College of Rheumatology revised criteria for the classification of systemic lupus erythematosus. *Arthritis Rheum*. 1997 Sep;40(9):1725.